

Diagnosing Denture Pain: Principles and Practice

Robert W. Loney, DMD, MS



Dr. Loney's full-day session at the CDA Annual Convention, titled "Making removable prostheses work," will be presented on Saturday, August 26. For more information on the 2006 CDA Annual Convention, to be held August 24–26 in St. John's, Newfoundland, visit the CDA website at www.cda-adc.ca.

Clinicians can use 5 strategies to save time and minimize repeat visits for patients who have problems with their complete or removable partial dentures: 1) establish the differential diagnosis, 2) identify variations from normal, 3) have the patient demonstrate the problem, 4) always use an indicating medium when making adjustments to prostheses and 5) have the patient rate perceived improvement after adjustments.

Establish the Differential Diagnosis

To eliminate a denture problem, its cause must first be correctly identified. Take a good history and perform a thorough clinical examination. Establish a list of potential causes (the differential diagnosis), rank them according to frequency, and begin by eliminating those most likely to be causing the problem in the particular patient. If the cause of the problem is correctly identified and addressed, the pain, ulceration and other related signs and symptoms should resolve in 10 to 14 days.¹ Biopsy is mandatory for any lesion that fails to heal within 14 days after onset,² particularly when a denture has

been ruled out as the source of the ulcer. Work down the list of possible diagnoses until the problem is solved.²

Diagnosing the problem requires a thorough history from the patient, including the following specific information:

- When did the pain start?
- How long does it last?
- What makes it better?
- What makes it worse?

Combined with information from the clinical examination, this information will help to establish the differential diagnosis, and the clinician can rank the most likely causes at the top of the list. The clinical examination should incorporate the strategies of identifying variations from normal, having denture patients demonstrate their problems and using an indicating medium.

Identify Variations from Normal

Many denture problems can be identified by inspecting the dentures critically for variations from normal (Figs. 1 to 7). Unusual extensions, contours, tooth positions, thickness and finish can all be sources of denture problems. Intraoral

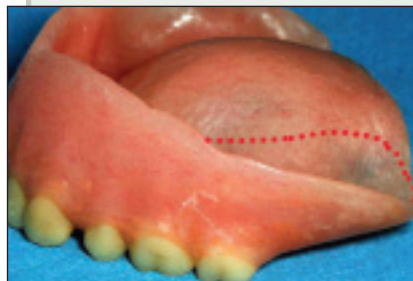


Figure 1: The posterior buccal flange of this denture is shorter than normal and should be extended to the dotted line. Compound or light-cured acrylic resin could be added to the periphery in an attempt to extend the border. When this approach was taken in this case, the patient's denture became markedly more retentive.

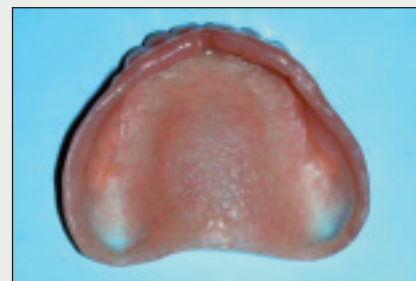

Figure 2: The transparent areas of resin over the tuberosities provide a clue that the lower denture is contacting the upper denture, thereby causing wear to the base. Such contact can cause the denture to loosen.

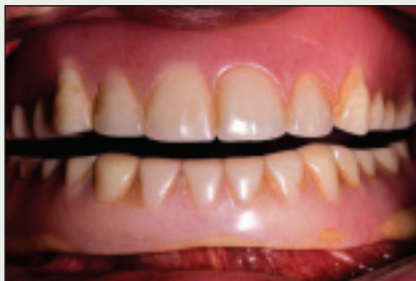

Figure 3: Severe and uneven wear on these dentures is responsible for esthetic problems, discomfort and difficulty chewing.

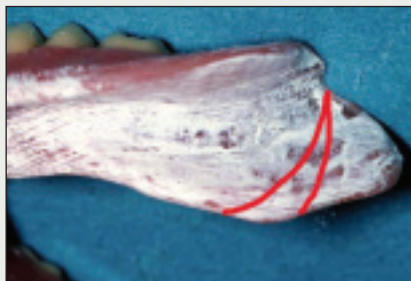

Figure 4: The distolingual flange of this mandibular denture looks different from a typical flange. Normally, the flange contour will either proceed straight down or arc gently downward and forward from the pear-shaped pad, but this one extends too far posteriorly from the position of the retromolar pad. This overextension caused pain on swallowing.

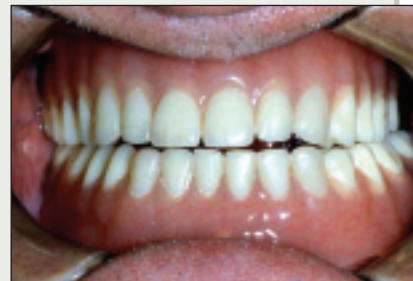

Figure 5: This patient had multiple sore spots associated with the denture, and previous adjustments to the denture bases had not provided any relief. The denture midlines are off, and the denture teeth in the second and third quadrants are meeting cusp to cusp, which suggests that poor occlusion could be the cause of the patient's problems.

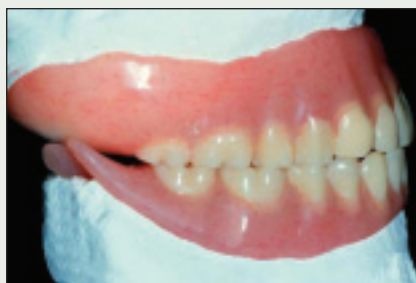

Figure 6: Posterior interferences between the denture bases can cause tipping of the dentures, which results in pain similar to that caused by occlusal problems.

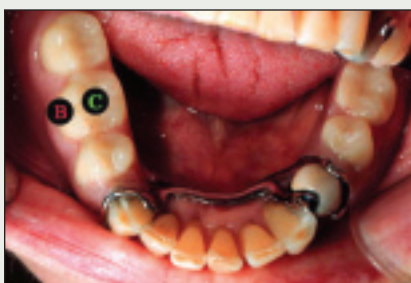

Figure 7: It is usually better to place and load posterior denture teeth centrally (C) over the ridge.³ More tipping problems result when occlusal forces are applied buccal to the ridge (B).⁴ These tipping problems can cause both looseness and pain.

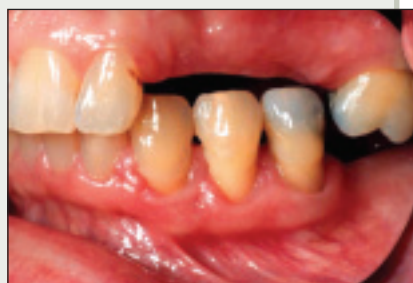

Figure 8: This patient had 3 unsuccessful maxillary partial dentures made within 1 year. Each time, she had requested only a new "upper plate and nothing else." However, all 3 dentures had failed because of fracture of the denture teeth and severe mobility of the prosthesis. The real problem was a lack of interarch space for the prosthesis, which the care providers had failed to identify because, in taking direction from the patient, they were looking only at the maxillary arch. The lesson from this case is that the clinical examination must be thorough, to ensure that all potential problems and variations from normal are identified.

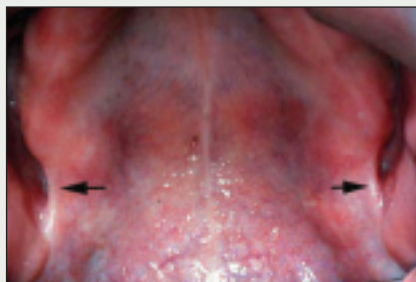

Figure 9: This patient has very tight pterygo-mandibular raphes (arrows). As the raphes tighten during opening, they pull on the posterior border of the denture, causing it to loosen (the patient's chief concern). Relief for these structures should be provided during the making of the impressions. This case emphasizes that anatomic variations must be identified to minimize denture problems.

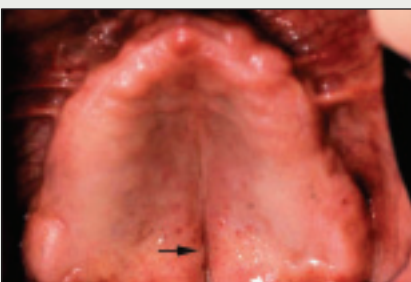


Figure 10: In this patient, the deep midline soft-tissue fissure at the posterior of the palate caused a break in the seal of the denture, which in turn caused looseness and dropping of the denture. Special attention is needed to ensure that the posterior palatal seal of the denture maintains tissue contact to provide adequate retention.

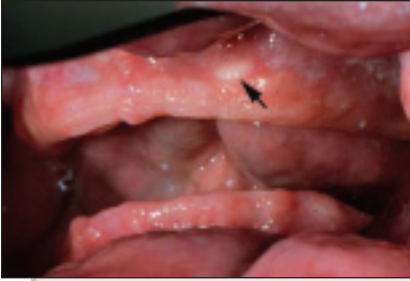

Figure 11: Ulcers, sore spots or areas of hyperkeratosis on the sides of the ridges, which are not identified by pressure indication medium, are typically caused by tipping of the denture. Tipping is frequently associated with occlusal problems.

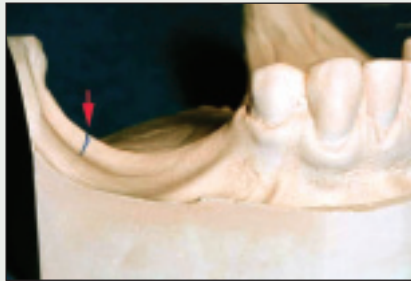


Figure 12: Posterior teeth set over the ascending portion of the ramus can cause a denture to slide or shift during function,⁵ causing occlusion-related pain. Therefore, do not set denture teeth posterior to the position indicated by the arrow.

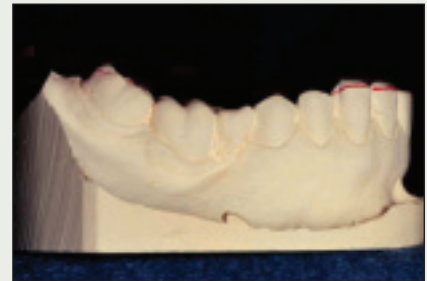

Figure 13: When a single denture opposes the natural dentition, the occlusal plane should not have a severe curve of Spee. Such a curve will place tilting forces on the denture in excursive movements, which frequently causes both looseness and discomfort.

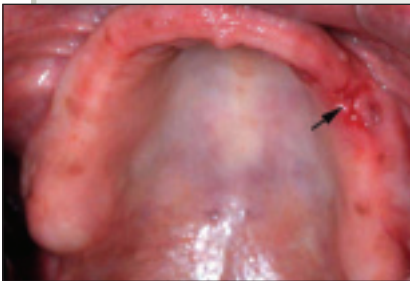


Figure 14: Areas of inflammation or ulceration that are caused by the denture base are often discrete and cannot be distinguished from similar areas related to occlusal problems. The diagnosis must be established through the history, a clinical examination and indicating medium. The definitive diagnosis is often determined by exclusion of other possible causes.

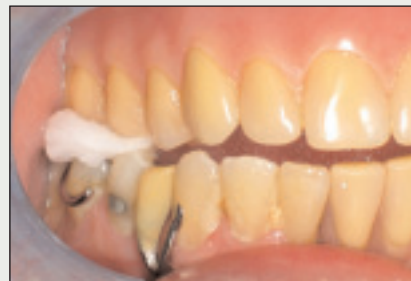

Figure 15: This patient is using a small piece of cotton roll to demonstrate where the maxillary denture loosens when he is chewing. Having patients demonstrate their problems while the dentist watches can often expedite the diagnosis of denture problems.

inspection for anatomic or tissue abnormalities or variants may also give clues to the cause of some denture problems (Figs. 8 to 14). If an abnormality is found and corrected, the signs and symptoms should resolve within 10 to 14 days.

Have the Patient Demonstrate the Problem

Asking the patient to demonstrate how the problem occurs often helps the clinician to identify its source. If the problem occurs only when the patient chews, cut a small piece of a cotton roll, dampen it, and let the patient demonstrate the location where the bolus causes the symptom (Fig. 15). If the problem occurs during speaking, singing, drinking or opening wide, have the patient replicate the circumstances. Have the patient describe what

they experience, and watch carefully to determine the cause of the problem. Attempt to eliminate the cause and recall the patient in 10–14 days to ensure that the signs and symptoms have resolved.

Use an Indicating Medium when Making Adjustments

Clinicians usually check occlusion of restorations using an indicator such as articulating paper or shim stock. Similarly, denture adjustments are more accurate and effective when an indicating medium is used. Pressure- or fit-checking medium, indelible markers and articulating paper can all be used to aid in locating a problem and determining the degree of adjustment that is required (Figs. 16 to 20).

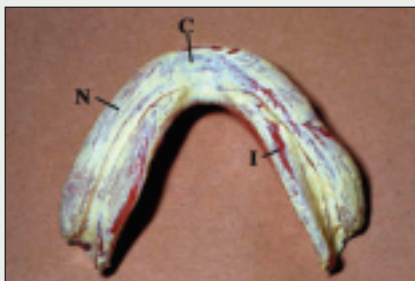

Figure 16: Pressure-indicating medium is necessary to identify denture base impingements. Apply the medium with a stiff bristle brush, coating the denture with enough paste so that the base is mostly the colour of the medium. Leave streaks in the paste. Place the denture intraorally, avoiding contact with cheeks and lips. Press firmly into place over the first molars. Do not tip, tilt or wiggle. Remove and inspect the denture. Areas with paste and no brush strokes represent areas of moderate tissue contact (C). Areas without paste (burn-through) represent areas of tissue impingement (I). Areas with streaks remaining in the paste have not contacted the tissue (N).



Figure 17: A well-adjusted denture base. Areas of tissue inflammation that do not correlate to areas of burn-through are most likely caused by tilting of the denture. Potential occlusal causes should be investigated.

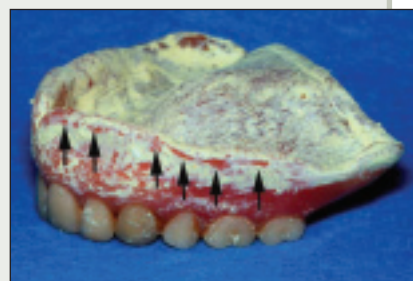

Figure 18: Lines of burn-through on flanges often indicate areas that are overextended or too thick. They may require repeated adjustments and applications of paste.

Box 1 Typical histories for patients with denture pain

For pain related to occlusion

- Hurts only when chewing
- Gets worse with chewing
- Gets worse as the day progresses
- Patient may have to remove prosthesis late in the day because of discomfort

For pain related to denture base fit

- Problem starts when the patient inserts the denture, which often feels tight or causes soreness
- Patient has discomfort even when not chewing
- May or may not get worse as the day progresses

For pain related to occlusal vertical dimension (OVD)^{5,6}

Insufficient OVD (Fig. 21)

- Lack of chewing power
- Minimal ridge discomfort
- Angular cheilitis
- Chin prominent
- Minimal display of vermilion border

Excessive OVD (Fig. 21)

- Soreness over entire ridge
- Worse during the day (increased occlusal contact)
- Dentures “click” when speaking
- Mouth feels “too full,” patient has difficulty getting lips together

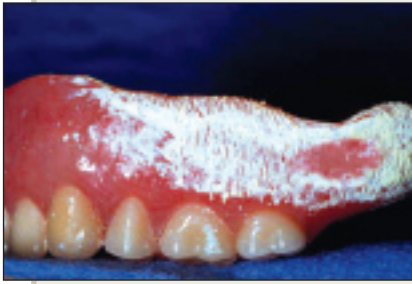

Figure 19: Pressure-indicating medium can be used on non-bearing surfaces of the denture to identify other undesirable contours. This photo demonstrates an impingement of the coronoid process on the posterior denture flange during lateral excursion. This interference caused both pain and loosening of the denture.

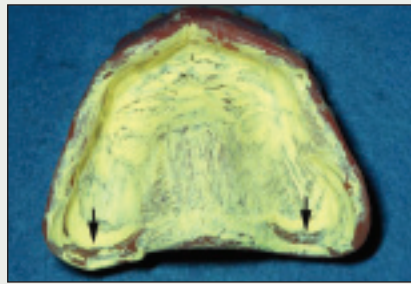


Figure 20: A sharp, thin or overextended periphery in the hamular notch area can cause painful ulcers. Use of indicating medium is critical for adjustment of these areas, because removal of acrylic in the wrong area can result in a breach of the posterior palatal seal, which will result in loosening of the denture and little relief of the discomfort.

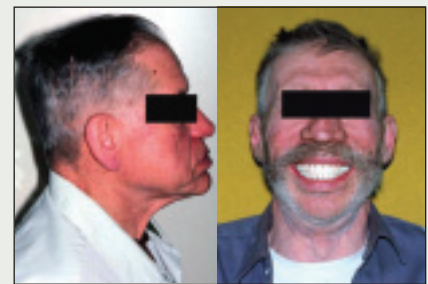

Figure 21: Examples of insufficient (left) and excessive (right) occlusal dimension. Although adjustments are sometimes helpful, a remake of the denture is usually required to completely resolve these serious denture problems.

Have the Patient Rate Perceived Improvement after Adjustments

If a clinician asks the patient whether a denture adjustment has made the situation better, the most likely response is “yes.” But if the adjustment has improved the situation by only 20%, the patient is likely to return with the same problem at a subsequent appointment. A better question is “How does that feel?” If the patient states that it feels “better,” he or she should be asked to rate how much better, in terms of a percentage. An ulceration may not feel 100% better at the end of an appointment, but the improvement should feel closer to 90% than to 20%.

Causes of Denture Pain

Possible causes of denture pain include occlusion, denture base (fit and contour), vertical dimension, infection, a systemic disease or condition, or an allergy (rare).

It is probable, although unproven, that occlusion and poor fit of the denture base cause more repeat visits for denture-related pain than the other causes listed. The latter 3 causes (infection, disease and allergy) should never be overlooked, especially when ulcers or pain are persistent despite interventions, but for the purposes of this paper, only the first 3 causes are addressed (Box 1).

Conclusion

Many clinicians deal with denture-related pain by grinding the denture base in the area of the

reported pain. This type of blanket solution is akin to a physician prescribing a broad-spectrum antibiotic to all patients who have a sore throat and runny nose. It assumes, incorrectly, that the denture base is the source of all denture pain. Clinicians can save time and minimize repeat visits for patients with denture problems when they use a systematic approach to correctly diagnose denture pain. ➤

THE AUTHOR



Dr. Loney is a professor and director of the graduate prosthodontics program in the department of dental clinical sciences, faculty of dentistry, Dalhousie University, Halifax, Nova Scotia. Email: robert.loney@dal.ca.

References

- Peterson LJ, Ellis E, Hupp JR, Tucker MR. Contemporary oral and maxillofacial surgery. 4th ed. St. Louis (MO): Mosby; 2003. p. 459.
- Sonis ST, Fang LS, Fazio R. Principles and practice of oral medicine. 2nd ed. Philadelphia: W.B. Saunders; 1995. p. 23–9.
- Zarb GA, Bolender CL. Prosthodontic treatment for edentulous patients: complete dentures and implant-supported prostheses. 12th ed. St. Louis: Mosby; 2003. p. 84, 314.
- Browning JD, Jameson WE, Stewart CD, McGarrah HE, Eick JD. Effect of positional loading of three removable partial denture clasp assemblies on movement of abutment teeth. *J Prosthet Dent* 1986; 55(3):347–51.
- Winkler S. Essentials of complete denture prosthodontics. 2nd ed. Littleton (MA): PSG Pub. Co.; 1988. p. 326–7.
- Watt DM, MacGregor AR. Designing complete dentures. 2nd ed. Bristol: John Wright; 1986. p. 142–59.